

COMPARATIVE ANATOMY ON OLFACTORY STRUCTURES OF SNAKEHEAD FISHES: A CLADISTIC APPROACH AND DOCUMENTATION

Swaraj Kumar Sarkar and Subrata Kumar De*

Ultrastructure and Fish Biology Research Unit, Department of Zoology,
Vidyasagar University, Midnapore (West) – 721 102, West Bengal, India

ABSTRACT ■ The olfactory apparatus in two different benthopelagic; snakehead fishes of *Channa punctatus* and *Channa striatus* (Channiformes: Channidae) were studied to explore the taxon based comparative morphometry among the experimental species. The olfactory apparatus of *C. punctatus* and *C. striatus* were separately fixed in aqueous Bouin's solution and 4% paraformaldehyde in 0.1 (M) phosphate buffer (pH. 7.2); studied under optical light microscopes. The distinct anatomical variations [*i.e.*, number of olfactory lamella in each rosette, diameter of olfactory chambers, shape and size of olfactory bulbs and lobes, length of olfactory nerve tracts, *etc.*] were examined. The histoarchitecture of olfactory rosette also shows prominent differences in arrangement pattern of olfactory lamellae, distribution of sensory and non-sensory cellular components, *etc.* These variations may reflect species specific differences belonging to genus *Channa* that helps in morphoanatomy based cladistic approach of fish taxonomy.

Key words: *Channa*, benthopelagic, olfactory, histoarchitecture, cladistic

INTRODUCTION

Teleosts are recognized as the most diverse taxonomic group among the vertebrates (Nelson 2006). This group possesses well developed olfactory apparatus that is involved in perception of chemical cues from the external aquatic environment (Hara 1971). This sense is regarded as the first chemosensory modality which is developed during the ontogeny of fish (Kotrschal *et al.* 1997). The gross anatomical detail on the olfactory apparatus was first reported by

Burne (1909). A wide range of anatomical variations in peripheral olfactory apparatus of teleosts were also reported (Kapoor and Ojha, 1972; Hansen *et al.* 2005; Hamdani and Døving 2007; Cox 2008; Sarkar *et al.* 2014a). Apart from that, the interspecific divergences in olfactory apparatus of teleostean species belonging to same Genus (*i.e.*, 'taxon based anatomical study') was less addressed in fish biology (Hansen and Zeilinski 2005). This study considered the olfactory apparatus in two different benthopelagic snakehead fishes

* Corresponding author : e-mail: skdvu@yahoo.co.in

belonging to the genus *Channa* to highlights the structural variation based cladistic analysis among the experimental species [*i.e.*, *Channa punctatus* (Bloch 1793) and *Channa striatus* (Bloch 1793)] [IUCN Red List Status: 'Least Concern'].

METHODOLOGY

Live, adult, sex-independent specimens of *C. punctatus* and *C. striatus* were collected from the local markets and brought to laboratory [Figs. 1A and 2A]. The healthy specimens were sorted out; acclimatized with the laboratory conditions at 32°C for 48 hours and anaesthetized by using MS-222 (dose: 100-200mg/L). Olfactory structures were dissected out from dorsal surface of the head, fixed in aqueous Bouin's solution [75ml of saturated aqueous Bouin's solution is added to 25ml of 35% -40% formaldehyde solution. 5ml of Glacial Acetic Acid is also added to prepare the fresh solution before use] and examined under binocular light microscope (LM). For microanatomical study, the olfactory apparatus was fixed in 4% paraformaldehyde in 0.1 (M) phosphate buffer (pH. 7.2) for 2 hours at 4°C. The fixed tissues were then washed in the same buffer (3 changes at 30 minutes of interval) and cryoprotected in 15% – 30% sucrose solution in 0.1 (M) phosphate buffer for 24 hours at 4°C. The frozen sections (thickness: 6 - 10µm) were cut by using cryostat (Leica CM 1850; Leica Biosystems Nussloch GmbH, Germany) and carefully placed on gelatin coated slides. The slides were stained with Hematoxylin – Eosin; examined under trinocular light microscope (Primo Star; Carl Zeiss Microscopy, GmbH, Germany) and acquired images were analysed by Axio Vision LE (version 4.3.0.101) (Carl Zeiss Vision, GmbH, Germany). The statistical data were also analyzed by using MS Excel 2016.

RESULTS

The olfactory apparatus in *C. punctatus* and *C. striatus* are located at the dorso-lateral part of snout. *C. punctatus* possess comparatively short and elliptical snout than *C. striatus* that shows elongated and pointed snout (Figs. 1B and 2B). The distances between the anterior and posterior nares are variable [*C. punctatus*: 1mm; *C. striatus*: 2mm] (Figs. 1B, 2B and Table 1). The olfactory apparatus of *C. punctatus* and *C. striatus* show similar structural components [*i.e.*, olfactory chambers, olfactory rosette, accessory nasal sacs, olfactory bulbs, olfactory nerve tracts, olfactory lobes and brain] (Figs. 1C and 2C). The olfactory rosette is a multilamellar structure but varies in number of olfactory lamella per rosette (*C. punctatus*: 18-20; *C. striatus*: 40-52) (Table 1). The orientation of rosette is also differing among *C. punctatus* and *C. striatus* (Figs. 1C and 2C). The olfactory rosettes of *C. punctatus* and *C. striatus* are externally lined by pseudostratified olfactory neuroepithelium (Figs. 1D and 2D). The olfactory lamellae in *C. punctatus* are triangular and pointed at the apical part (Fig. 1D). The length of the olfactory lamella is gradually increased towards the middle of rosette (Fig. 1D). In *C. striatus*, the olfactory lamellae are densely radiated from the floor of the olfactory chamber (Fig. 2D). The apical tip of the olfactory lamella is rounded and blunt in nature (Fig. 2D). The occurrences of neuroepithelial cellular components in both the species is similar. (Figs. 1E and 2E). The sensory receptor cells are bipolar neuron in nature and their perikaryon are located at the different depth of the olfactory neuroepithelium (Figs. 1E and 2E). The perikaryon of sensory receptor cell possess spherical nucleus (diameter: 1.2 µm to 2.0 µm). In *C. punctatus* and *C. striatus*, the sensory receptor cells are mostly distributed throughout the olfactory neuroepithelium.

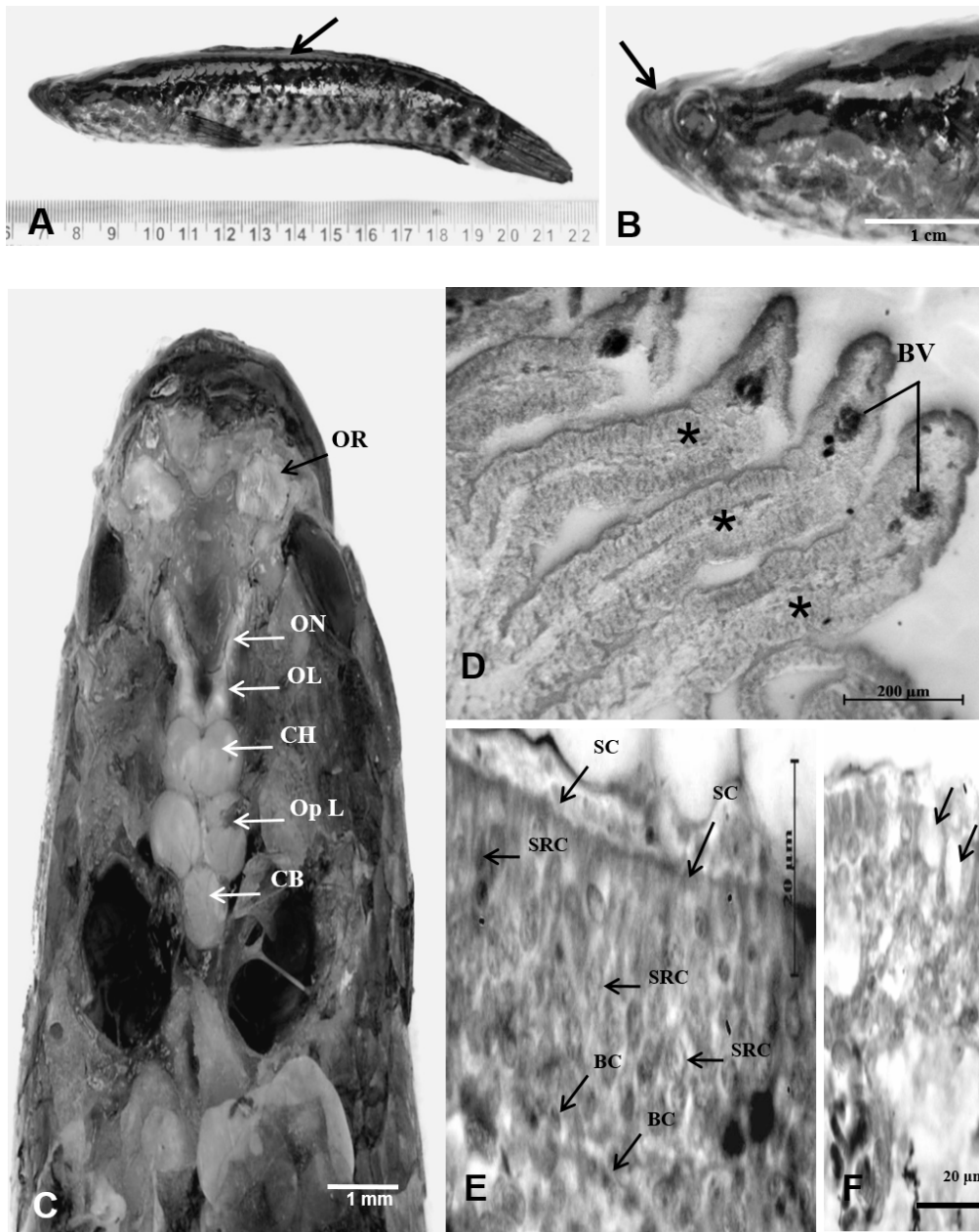


Figure 1 – A: The photograph shows an adult specimen of *Channa punctatus* (Bloch, 1793) [arrow] B: The Snout of *C. punctatus* is elliptical in shape (arrow). Anterior and posterior nares are marked at the dorsal side of snout. C: The structural organization of olfactory apparatus in *C. punctatus*, includes olfactory rosette (OR), olfactory bulb (OB), accessory nasal sac (ANS), olfactory nerve tract (ON), olfactory lobe (OL), cerebral hemisphere (CH), optic lobe (Op L), cerebellum (CB) and medulla oblongata (MO). D: The microanatomical photograph indicates olfactory lamellae (stars), oriented dorsally from olfactory chamber. Blood vessels (BV) are present at the apical part of lamella. E: The olfactory neuroepithelium of *C. punctatus* shows sensory receptor cells (SRC), supporting cells (SC) and basal cell (BC) at the variable depths. F: Goblet cells (arrows) are also marked at the upper part of olfactory neuroepithelium.

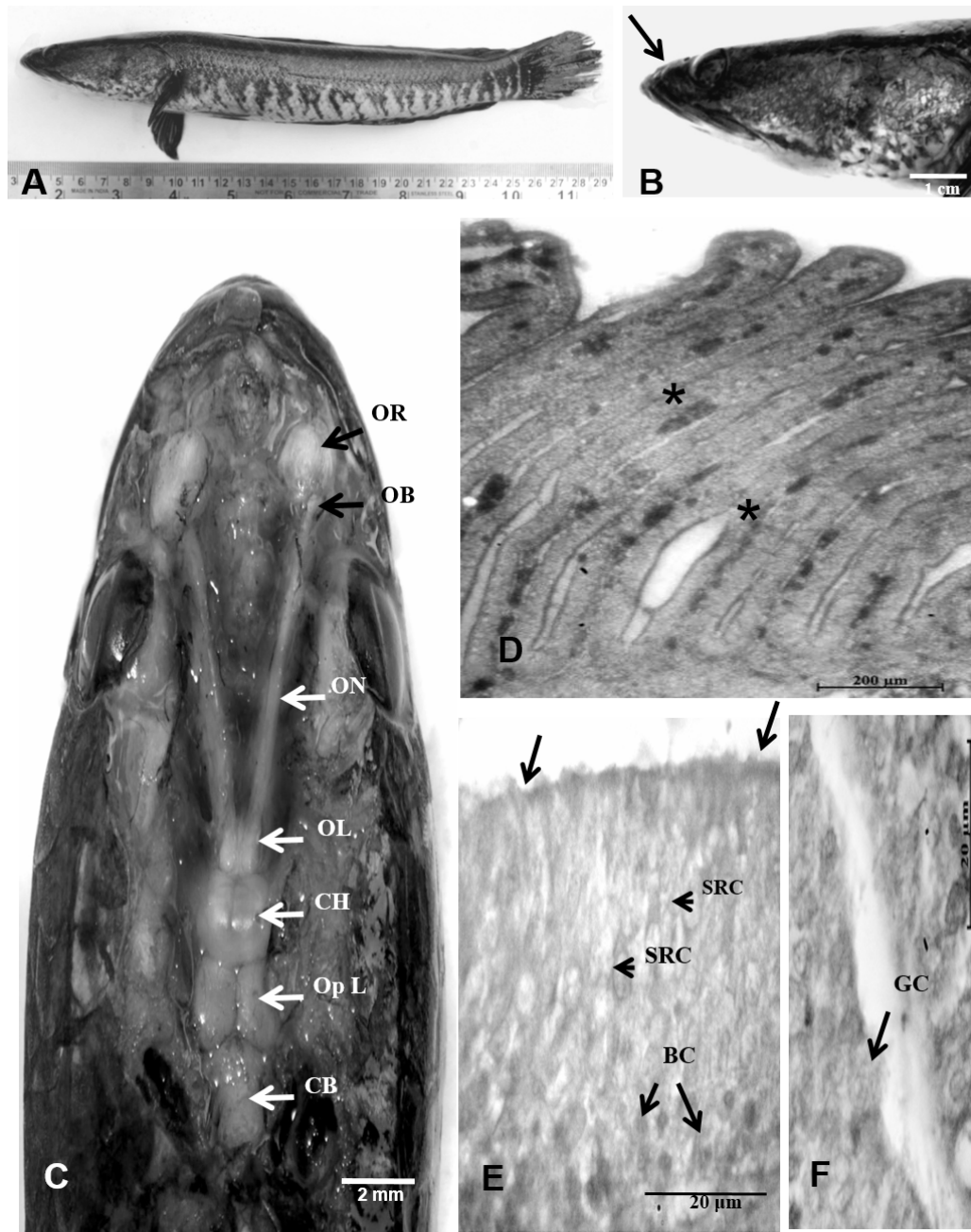


Figure 2 – A: The photograph indicates an adult specimen of *Channa striatus* (Hamilton, 1822) [arrow]. **B:** The snout of *C. striatus* is elongated (arrow). **C:** The anatomical organization of olfactory apparatus in *C. striatus* which comprised of olfactory rosette (OR), olfactory bulb (OB), accessory nasal sac (ANS), olfactory nerve tract (ON), olfactory lobe (OL), cerebral hemisphere (CH), optic lobe (Op L), cerebellum (CB) and medulla oblongata (MO). **D:** The photograph shows that elongated olfactory lamellae (stars) within the rosette, oriented dorsally from the floor of olfactory chamber. **E:** The pseudostratified olfactory neuroepithelium, shows sensory receptor cells (SRC), supporting cells (arrows) and basal cell (BC). **F:** Goblet cell (GC) is frequently noted within the olfactory neuroepithelium of *C. striatus* than *C. punctatus*.

Table 1: The table shows comparative morphoanatomical account on olfactory structures of *C. punctatus* and *C. straitus*

	Total body length (TL)	Average distance between nares	No. of lamella/ rosette	Epithelial thickness (average)		Average Diameter of blood capillaries
				Proximal (μm) \pm SD	Distal (μm) \pm SD	
<i>C. punctatus</i>	(15 – 20)cm	1mm	18 – 20	24.31 \pm 0.01	13.35 \pm 0.01	25.17 μm
<i>C. straitus</i>	(15 - 20)cm	2mm	40 - 52	25.58 \pm 0.015	20.42 \pm 0.015	21.01 μm

Table 2: The tabulated representation of similar distribution pattern of Epithelial cells of Olfactory neuroepithelium in *C. punctatus* and *C. straitus*

	Ciliated Sensory receptor cell		Microvillous Sensory Receptor Cell		Differentiating stages of Basal Cell		Basal Cell	
	Proximal part of OE	Distal Part of OE	Proximal part of OE	Distal Part of OE	Proximal part of OE	Distal Part of OE	Proximal part of OE	Distal Part of OE
<i>C. punctatus</i>	Present	Present	Present	Present	Present	Present	Present	Absent
<i>C. straitus</i>	Present	Present	Present	Present	Present	Present	Present	Absent

Table 3: The comparative account on olfactory neuroepithelial cellular morphometry in *C. punctatus* and *C. straitus*

	Ciliated Sensory Receptor Cell (at proximal part of olfactory epithelium)			Microvillous Sensory Receptor Cell (at proximal part of olfactory epithelium)			Goblet cell (μm) \pm SD	Basal Cell (μm) \pm SD
	Av. Length of Dendron (μm) \pm SD	Av. Diameter of Perikaryon (μm) \pm SD	Av. length of Axon (μm) \pm SD	Av. length of Dendron (μm) \pm SD	Av. Diameter of Perikaryon (μm) \pm SD	Av. length of Axon (μm) \pm SD		
<i>C. punctatus</i>	6.81 \pm 0.01	2.25 \pm 0.01	8.48 \pm 0.01	3.01 \pm 0.01	2.28 \pm 0.01	14.02 \pm 0.01	3.70 \pm 0.01	1.42
<i>C. straitus</i>	7.80 \pm 0.01	2.52 \pm 0.01	10.85 \pm 0.01	3.70 \pm 0.01	2.58 \pm 0.01	7.12 \pm 0.01	4.41 \pm 0.01	1.82

The middle and proximal part of olfactory lamella predominantly shows goblet cells (Figs. 1E, 2E, 1F, 2F and Tables 2 & 3). The columnar supporting cells are frequently noted within the olfactory neuroepithelium in both species (Figs. 1E and 2E). The small and polygonal basal cells are located above the basal lamina (Figs. 1E and 2E). The blood capillaries in lamina propria of *C. punctatus* is present at the apical part of olfactory lamella

where as in *C. straitus*, large blood capillaries are predominantly present at the base of the olfactory lamella (Figs. 1F and 2F). Just beneath the olfactory rosette, an oval shaped olfactory bulb is marked (Figs. 1C and 2C). The diameter of the olfactory bulb in *C. straitus* is apparently greater than *C. punctatus*. The olfactory nerve is generally arising from the posterior part of the olfactory bulb and well connected with the olfactory lobe of the

forebrain (Figs. 1C and 2C). In *C. punctatus*, the olfactory nerve tracts are comparatively short and stumpy (length: 6mm) (Fig. 1C) whereas the olfactory nerve tracts in *C. striatus* are very long (length: measured about 12mm) (Fig. 2C). The subdivisions of brain (*viz.*, cerebral hemisphere, optic lobe, cerebellum, medulla oblongata, *etc.*) are quite similar in both the experimental specimens (Figs. 1C and 2C).

DISCUSSION

The morphological study is an essential trait in taxonomical practice which also correlates phylogenetic interrelationship. The value of morphological phylogenetics was critically evaluated by Scotland *et al.*, (2003) to resolve phylogeny at lower or higher taxonomic level. The morphological phylogeny includes both homology and heterogeneity of morphological data for reconstruction of phylogenetic distance among species. The olfactory apparatus of teleosts shows a considerable variation among the different groups (Hara 1971). These variations may represent ecological habitat based morphological adaptation of a species (Kleerekoper 1969; Sarkar *et al.* 2014a). The ecological factors directly influence the external morphology of teleosts (Kotrschal *et al.* 1998; Sarkar *et al.* 2014a). Although, *C. punctatus* and *C. striatus* are occupying same ecological conditions (benthopelagic habitat) but shows considerable variations in anatomical organization of olfactory apparatus. Variation in snout is an important criterion of anatomical diversity of olfactory apparatus of teleosts even between the species belonging to the same genus. In *C. striatus*, the distance between nares and number of olfactory lamella are greater than *C. punctatus* which is significantly correlated with increasing the neuroepithelial surface for

olfaction. The rosette is formed by the subsequent folding of olfactory neuroepithelium during morphogenesis (Sarkar *et al.* 2014b). The occurrence of different neuroepithelial cells (*viz.*, sensory receptor cell, supporting cell, goblet cell, basal cell, *etc.*) in olfactory neuroepithelium was quite similar in *C. punctatus* and *C. striatus*. The comparative demarcations in histoarchitecture of olfactory neuroepithelium and arrangement pattern of olfactory lamellae are representing difference between the species. The variable length of olfactory nerve tracts is also a notable character of these species. The distance between the rosette and brain is also different. Cladistic classification of species is exclusively depends on the structural variations of a concerned organ but similarities may indicate origin from common ancestor (Hennig 1950; Simpson 1961). Therefore, these taxa based comparative anatomical variations are the prime requisite for demonstrating the cladistic mapping in fish taxonomy.

ACKNOWLEDGEMENTS

We are thankful to Director, USIC, Vidyasagar University, Midnapore (West) – 721102, West Bengal for his necessary support.

REFERENCES

- Burne, R.H. (1909): The anatomy of the olfactory organ of teleostean fishes. Proceedings of Zoological Society London, 2: 610-663.
- Cox, J.P.L. (2008): Hydrodynamic aspects of fish olfaction. Journal of the Royal Society Interface, 5: 575-593.
- Hamdani, E.H. and Døving, K.B. (2007): The functional organization of the fish olfactory system. Progress in Neurobiology, 82: 80 – 86.
- Hansen, A., Rølen, S.H., Anderson, K., Morita, Y., Caprio, J. and Finger, T.E. (2005): Olfactory receptor neurons in fish: structural, molecular and

- functional correlates. *Chemical Senses*, 30: 1, i311.
- Hansen A. and Zielinski, B.S. (2005): Diversity in the olfactory epithelium of bony fishes: development, lamellar arrangement, sensory neuron cell types and transduction components. *Journal of Neurocytology*, 34: 183–208.
- Hara, T.J. (1971): Chemoreception. In: Hoar, W.S. and Randall, D.J. (eds), *Fish physiology* 5. Academic Press, New York. 79-120.
- Hennig, W. (1950): Grudnzuege einer theorie der phylogenetischen systematik, Deut zentral-verlage., Berlin. p. 370.
- Kapoor, A.S. and Ojha, P.P. (1972): Functional anatomy of the olfactory organs in the moray, *Muraena undulata*. *Japanese Journal of Ichthyology*, 19 (2): 82 - 88.
- Kleerekoper, H. (1969): *Olfaction in Fishes*. Indiana University Press, Bloomington and London.
- Kotrschal, K., Krautgartner, W. and Hansen, A. (1997): Ontogeny of the Solitary Chemosensory Cells in the Zebrafish, *Danio rerio*, *Chemical Senses*, 22: 111-118.
- Kotrschal, K., Staaden, M.J.V. and Huber, R. (1998): Fish brains: evolution and environmental relationship. *Reviews in Fish Biology and Fisheries*, 8: 373-408.
- Nelson, J.S. (2006): *Fishes of the World* (Fourth Edition), John Wiley & Sons, USA.
- Sarkar, S.K., Acharya, A., Jana, S. and De, S.K. (2014a): Macro-anatomical variatiobn of the olfactory apparatus in some in some Indian teleosts with special reference to their ecological habitat. *Folia Morphologica (Warsz)*, 73 (2): 122 – 128.
- Sarkar, S.K., Biswas, S., Datta, N.C. and De, S.K. (2014b): Postnatal development of olfactory apparatus in *Labeo rohita* (Hamilton, 1822). *International Journal of Science and Nature*, 5 (1): 480 - 485.
- Scotland, R.W., Olmstead, R.G. and Bennett, R. (2003): Phylogeny reconstruction: The role of morphology. *Systematic Biology*, 52 (4): 539-548.
- Simpson, G.G. (1961): *Principles of Animal Taxonomy*. Columbia University Press, New York. p. 247.

